

Supplementary information

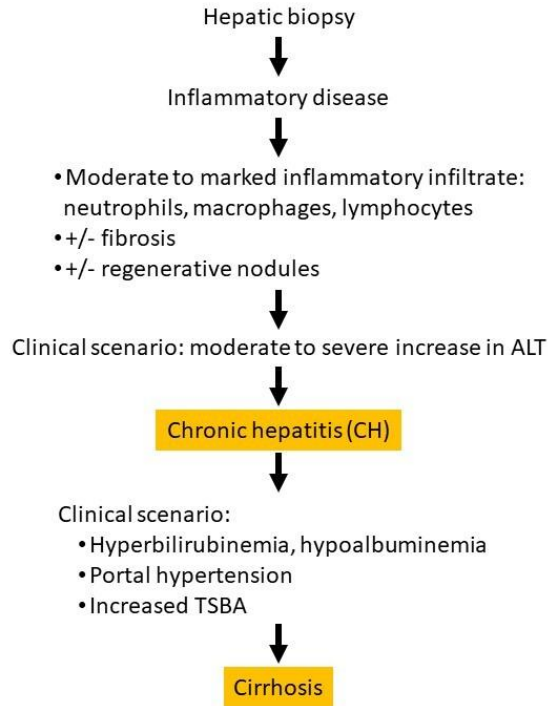


Figure S1. Panel for the diagnosis of liver diseases. Primary chronic inflammatory hepatopathies in dogs are usually accompanied by hepatocyte necrosis/apoptosis as well as different degrees of fibrosis. The integration of clinical signs and pathology, diagnostic imaging, and hepatic biopsy is required.